



E-ISSN: 2278-4136  
P-ISSN: 2349-8234  
JPP 2019; 8(5): 844-848  
Received: 13-07-2019  
Accepted: 17-08-2019

**Priya Meravi**  
College of Veterinary Science &  
Animal Husbandry NDVSU,  
Jabalpur, Madhya Pradesh,  
India

**Amita Tiwari**  
College of Veterinary Science &  
Animal Husbandry NDVSU,  
Jabalpur, Madhya Pradesh,  
India

**Brejesh Singh**  
College of Veterinary Science &  
Animal Husbandry NDVSU,  
Jabalpur, Madhya Pradesh,  
India

**Arun Mourya**  
College of Veterinary Science &  
Animal Husbandry NDVSU,  
Jabalpur, Madhya Pradesh,  
India

**RPS Baghel**  
College of Veterinary Science &  
Animal Husbandry NDVSU,  
Jabalpur, Madhya Pradesh,  
India

**Correspondence**  
**Priya Meravi**  
College of Veterinary Science &  
Animal Husbandry NDVSU,  
Jabalpur, Madhya Pradesh,  
India

## Emerging threats of sheep associated malignant catarrhal fever in India: A review

**Priya Meravi, Amita Tiwari, Brejesh Singh, Arun Mourya and RPS Baghel**

### Abstract

Malignant catarrhal fever (MCF) is a fatal lymphoproliferative disease of cattle and other ungulates caused by the ruminant gamma-herpesvirus, *Alcelaphine herpesvirus-1* (AIHV-1) and *Ovine herpesvirus-2* (OvHV-2). AIHV-1 naturally infects wildebeest and causes wildebeest associated malignant catarrhal fever and OvHV-2 infects all varieties of domestic sheep as a subclinical infection and causes sheep associated malignant catarrhal fever.

Sheep associated malignant catarrhal fever (SA-MCF) is an emerging disease in India caused by *Ovine herpesvirus-2* which is enzootic worldwide in domestic sheep and transmitted to ruminants including pigs. OvHV-2 is transmitted by contact or aerosol, mainly from less than a year old lambs. Vinod *et al.* have investigated outbreak of sheep associated malignant catarrhal fever in crossbred cattle in village of Andhra Pradesh. Incubation period of the disease ranges from 11-73 days. Clinical signs are generally widespread and involve many organs. Infected cattle may be presented in five distinct forms: peracute form, head and eye form, alimentary form, neurological form and cutaneous form. Typical signs of the disease are corneal opacity, mucopurulent nasal discharge, erosions on tips of buccal papillae etc. Diagnosis of SA-MCF poses significant challenges to veterinarians due to multi-systemic involvement of the disease and symptomatic resemblance to many other diseases in field. The clinical differential diagnosis of MCF should include BVD, FMD, rinderpest, blue tongue, IBR. Virus can be detected by PCR and serological tests as ELISA, CFT and Competitive inhibition enzyme linked immunosorbent assay. Many therapeutic attempts have been described, including the use of corticosteroids, antibiotics, antivirals, vitamins and other supportive treatments. Medical treatment of cattle comprised one or more of following: procaine penicillin, ceftiofur sodium, oxytetracycline, sulfadimethoxine etc. The recent availability of derivatives of acyclovir compounds that inhibit replication of herpesviruses shows promise in potential treatment regimens.

With spread to a large part of the world, SA-MCF has become one of the emerging diseases of ruminants. The prevention of contact between carriers and clinically susceptible species remains the primary method of disease control.

**Keywords:** Emerging threats, associated malignant, catarrhal fever

### Introduction

Malignant catarrhal fever (MCF) is a fatal lymphoproliferative disease of cattle and other ungulates caused by the ruminant Gamma-herpesviruses, *Alcelaphine herpesvirus-1* (AIHV-1) and *Ovine herpesvirus-2* (OvHV-2) [7].

Globally two endemic forms of MCF with distinct geographical distribution exists. *Alcelaphine herpesvirus-1* (AIHV-1) naturally infects wildebeest and causes wildebeest associated MCF (WA-MCF) in cattle in regions of African sub-continent. The *Ovine herpesvirus-2* (OvHV-2) infects all varieties of domestic sheep as a sub-clinical infection and causes sheep associated MCF in susceptible ruminants in most regions of the world.

These viruses cause inapparent infection in their reservoir hosts (wildebeest for AIHV-1 and sheep and goat for OvHV-2) but fatal lymphoproliferative disease when they infect MCF-susceptible hosts (Bison for AIHV-1 and cattle, water buffalo, bateng, antelopes and pigs for OvHV-2) [16].

Sheep associated malignant catarrhal fever is an emerging and an important disease of cattle and it is particularly significant in the Indian context where mixed farming is common practice. In India, there is mixed livestock farming system of cattle with sheep and goats which leads to increased chances of close contact of carrier animals with clinically susceptible animals.

In India, the detection of cases of SA-MCF in cattle and OvHV-2 infection in sheep during the last decade has established the presence of the virus in native sheep of the country [18].

This disease is on the list of notifiable disease to the World Organisation for Animal Health (OIE) [1]. Due to recent clinical cases of sheep associated malignant catarrhal fever in cattle in India and subsequent detection of OvHV-2 in these animals, this virus has caught attention in India also.

### Etiology

The disease is caused by *Ovine herpes virus-2* (OvHV-2) which is enzootic worldwide in domestic sheep and transmitted to a wide variety of domestic and wild ruminants, including pigs [18]. This virus is belonging to family-Herpesviridae, subfamily – Gammaherpesvirinae and genus-Macavirus.

### Host range

Sheep are the original host of OvHV-2 but the infection may naturally be transmitted to cattle, bison, deer and pigs. Goats can also act as a source of OvHV-2 infection for cattle. There is a wide spectrum of species-susceptibility to OvHV-2-induced disease, ranging from relatively resistant cattle species (*Bos taurus* and *B. indicus*) and cases are usually sporadic, to much more susceptible deer species, bison (*Bison bison*) and water buffalo (*Bubalus bubalis*), to extremely susceptible Bali cattle (*Bos javanicus*) and deer (*Elaphurus davidianus*).

Although animals of the order Perissodactyla, family Equidae, have previously been considered not susceptible to *ovine herpesvirus 2* (OvHV-2) but recently found that horses may be infected by this virus [13].

### Transmission

The OvHV-2 is transmitted by contact or aerosol, mainly from less than a year old lambs. Lambs are infected usually at 3-6 months of age by aerosol transmission from other individuals within the flock and begin to actively shed virus at 6-9 months of age. Shedding decreases at 10 months with adults shedding at a much lower rate than adolescents [8]. Adult sheep can be infected by OvHV-2 via horizontal transmission through natural contact and it may intermittently shed large quantities of virus from nasal secretions.

Clinically susceptible species acquire the virus through inhalation, although ingestion of virus-laden secretions from contaminated feed or water has also been suggested as a route of transmission [4].

Colostrum and milk samples from infected ewes are strongly positive for OvHV-2 DNA, which suggests that mammary secretions could serve as an important source of infection for newborn lambs [9].

High levels of OvHV-2 DNA in the semen of rams and suggested an important role for sexual transmission of this disease [5].

- Transmission may be occur by following routes
- Inhalation
- Contaminated food and water
- Close contact
- Mammary secretion
- Semen of Rams

### Incidences and Epidemiology

Li *et al.* [10] reported that in petting zoo in Arizona, 17 deer from five different species, died due to OvHV-2 virus over a period from late 1992 to early 1995.

Imai *et al.* [6] investigated experimental transmission of sheep associated malignant catarrhal fever from sheep to Japanese deer (*Cervus Nippon*) and Cattle.

Wani *et al.* [23] have reported that the overall prevalence of OvHV-2 infection in the cattle in the Kashmir region was estimated to be less than 1 per cent.

Bremer [2] have reported 77% of the virus in 4 sheep breeds of various region of South Africa.

Luvizzotto *et al.* [23] reported 6.3% MCF prevalence in north eastern region of Brazil. Yesilbeg *et al.* [24] have reported 37% prevalence in sheep, 84.2% in goats and 14.2% in Lama in a study conducted for serological identification of OvHV- 2 in captive ungulates in Turkish zoo.

Sood *et al.* [18] have reported clinical cases in a captive female bison which died within three days of development of clinical symptoms from Bannerghatta National Park, Bangalore.

Palmer *et al.* [13] investigated active and latent OvHV-2 infection in captive herd of white tailed deer (*Odocoileus virginianus*) and found latent infection in this herd positive in 23/32 (72%) clinically normal deer.

Vinod *et al.* [21] have investigated outbreak of sheep associated malignant catarrhal fever in crossbred cattle in a village of Andhra Pradesh between December and January 2013–14.

Premkrishnan *et al.* [14] have reported that the prevalence of OvHV-2 infection in sheep population of Karnataka was 24.44%.

### Pathogenesis

The pathogenesis of MCF consists of three components

- T-lymphocyte hyperplasia in lymphoid organs and accumulation of these cells in non-lymphoid tissues
- Epithelial degeneration/necrosis and hyperkeratosis
- Vasculitis

Plowright as the first to suggest that immune mechanisms were responsible for their development which involved a hypersensitivity to viral or viral-induced antigens [22].

### Clinical signs

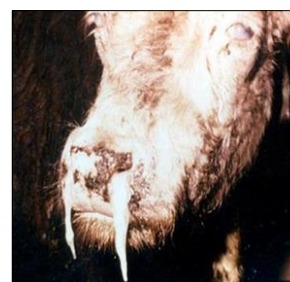Incubation period of the disease ranges from 11-73 days. MCF in cattle may be presented in distinct forms of clinical disease: peracute form, head and eye form, alimentary form, neurological form and cutaneous form.

### Per-acute form

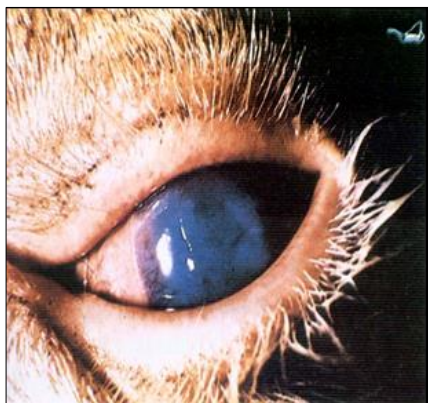This form lasts for 1–3 days. There is usually high fever, dyspnoea and an acute gastroenteritis.

### Head and eye form

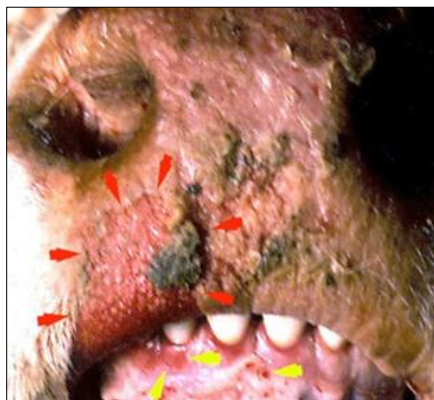Typical signs of head and eye form are opacity of the cornea, with a narrow grey ring at the corneo-scleral junction. The characteristics of this form include high fever (40–41 °C), mucopurulent nasal discharge, dyspnea due to nasal cavity obstruction, lymphadenopathy and blepharospasm [18]. The muzzle and nares are usually encrusted and the superficial lymph nodes are often markedly enlarged in cattle.



**Fig 1:** Mucopurulent nasal discharge



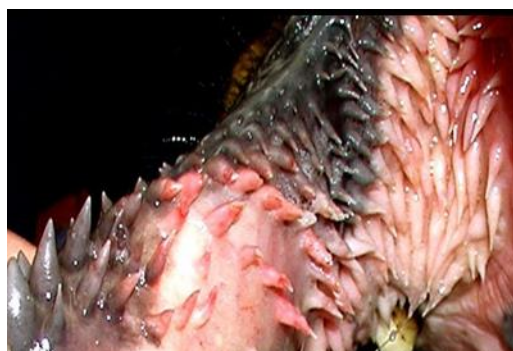**Fig 2:** Corneal opacity, Conjunctivitis and reddening of eye- lids



**Fig 3:** Focal ulceration of oral mucosa and sloughing of epidermis on muzzle

#### The alimentary form

The alimentary form has several of typical symptoms of head and eye form except that there are only minor eye changes and pronounced diarrhea <sup>[15]</sup>. The oral mucosa is often hyperemic and may contain multifocal or diffuse areas of necrosis. Erosions may be found at the tips of the buccal papillae.



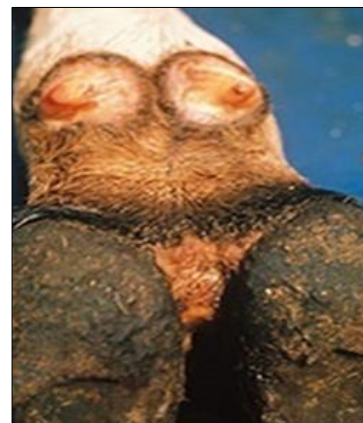**Fig 4:** Inflamed, discoloured and eroded oral papillae

#### Neurological form

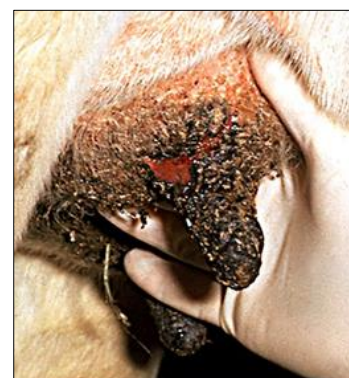
Early stages of neurological form involves nervous signs with weakness in one leg, in-coordination, muscle tremor and demented appearance. The final stage of this form includes head pressing, nystagmus and paralysis which are typical signs <sup>[18]</sup>.

#### Cutaneous form

In this form skin is erythematous or ulcerated and hardene, scabs may develop particularly on the perineum, udder and teats. Horn and hoof coverings may be loosened or sloughed. The joints may be swollen and milk production often drops.



**Fig 5:** Erosive and ulcerative Interdigital dermatitis



**Fig 6:** Inflamed skin of teats and udder become dry thickened and cracked leading to fissure formation

#### OvHV-2 infection in Cervids

The incubation period ranges from 7-25 weeks. Clinical signs involve conjunctivitis, corneal opacity, fibrin clots in the anterior eye chamber. Erosive-ulcerative mucosal lesions in the nose and mouth are also commonly found <sup>[20]</sup>.

#### OvHV-2 infection in foals

In diseased foals, clinical signs are severe dyspnea, profuse sweating with muscular spasms rigidity of the neck and limbs. Later on difficulty in standing and hind-limb paralysis may be seen.

#### Post mortem lesions

Gross findings at post-mortem examination include petechial haemorrhages on the tongue, buccal mucosa, in the gastrointestinal and respiratory tracts and urinary bladder. Commonly, there are raised pale foci on the surfaces of the kidneys and these may extend into the cortex. There is general enlargement of lymph nodes.

#### Diagnosis

Diagnosis of SA-MCF poses significant challenges to veterinarians due to multi-systemic involvement of the disease and symptomatic resemblance to many other diseases in the field and its complex pathogenesis. A complete history of the affected animal along with clinical symptoms and its contact with carrier species, grazing habits, calving, type of rearing etc. are important to arrive to a tentative diagnosis. However, confirmatory diagnosis is based on laboratory tests.

#### Histopathological examination

Samples will be obtained from the lungs, heart muscle with carotid artery, brain (cerebrum, cerebellum, midbrain), lymph



nodes, tonsil, liver, kidneys, adrenal glands, ureter, tongue, bile duct, bronchial wall, blood vessels and eye (cornea, lens, choroid).

Histopathological examination demonstrated fibrinous oedema and necrosis in the lymph nodes, vasculitis in blood vessels of the brain and kidney. Mononuclear infiltration in the adrenal glands, necrotic liver and chronic cholangitis and infiltration of the lymphocytes in the portal areas <sup>[4]</sup>.

### Polymerase chain reaction

OvHV-2 has never been identified formally, although lymphoblastoid cell lines propagated from affected animals contain OvHV-2 specific DNA and virus particles have been observed in these cells.

Viral DNA can be detected in clinical material from cases of MCF caused by OvHV-2 using the polymerase chain reaction. PCR is becoming the method of choice for diagnosing the disease.

Any animals that are suffering from MCF will have sufficient levels of viral DNA in their leukocytes and tissues to be readily detected by PCR. EDTA-anticoagulated blood should be submitted from live animals for PCR for peripheral blood leukocyte DNA.

### Serological test

Antibody of OvHV-2 can be detected by using AIHV-1 as the source of antigen. Domestic sheep consistently have antibody that can be detected by immunofluorescence, ELISA or immunoblotting. Complement fixation test <sup>[17]</sup> and competitive inhibition enzyme linked immunosorbent assay can also be used.

### Differential diagnosis

The clinical differential diagnosis of MCF should include bovine viral diarrhoea/mucosal disease, foot and mouth disease, blue tongue, rinderpest and infectious bovine rhinotracheitis but the stated diseases do not show ocular (kerato-conjunctivitis), enlargement of lymph nodes and signs of encephalitis

### Treatment

The recent availability of derivatives of acyclovir compounds that inhibit replication of herpesviruses shows promise in potential treatment regimens.

In order to prevent secondary bacterial infection drugs like oxytetracycline and sulphadimidin, procaine penicillin, ceftiofur sodium can be administered through parenteral route. Supportive treatment with flunixin meglumine and vitamin A have been suggested. Corticosteroid may be used as a life saver <sup>[12]</sup>.

### Prevention and control

There are no vaccines available till date. In India a mixed livestock farming system of cattle with sheep and goats, is most common which leads to increased chances of close contact of carrier animals (sheep and goat) with clinically susceptible animal such as cattle and buffaloes while housing or grazing. Certain points to keep in mind for control of the disease are enlisted below:

- Segregation of the susceptible host from the reservoir hosts is most important step for control of the disease.
- If cattle and sheep are reared under natural flock conditions, the grazing areas should be separate.

- A program to produce sheep free of infection should be initiated in which lambs are removed from contact with infected sheep prior to 2 months of age.
- Zoological parks should only introduce only sero-negative animals.
- The distance of separation between sheep and susceptible species should be as great as possible that should be at least 1000 meters if not further.

### Conclusion

With spread to a large part of the world, MCF has become one of the emerging diseases of ruminants. Due to its sporadic nature and overlapping clinical signs it produces, the disease is now receiving due attention in our country. With development of PCR based assays and their improved versions, it has now become easier to know the status of this disease. Currently, there is no policy in place related to the control of MCF. However segregation of the susceptible host from the reservoir hosts is most important step for control of the disease. A program to produce sheep free of infection should be initiated. Zoological parks should introduce only sero-negative animals.

### References

1. AU-IBAR. Malignant catarrhal fever, 2013, online <http://www.cabi.org>.
2. Bremer CW. The prevalence of *ovine herpesvirus 2* in 4 breeds from different regions in South Africa. *Journal of South African Veterinary Association*. 2010; 81:93-96.
3. Costa EA, Bomfim M, Fonseca FG, Drumond BA, Coelho FM, Vasconcelos AC *et al*. *Ovine Herpesvirus 2* infection in Foal, Brazil. *Emerging Infectious Diseases*. 2009, 15:844-845.
4. Gelaye E, Mekonnen GA, Jenberie S, Ayelet G. Detection of sheep associated malignant catarrhal fever from clinical cases in Ethiopian Cattle. *Revue Scientifique Et Technique-Journals*. 2013; 32:851-856.
5. Hussy D, Janett F, Albini S, Stauber N, Thun R, Ackermann M. Analysis of Pathogenetic Basis for Shedding and Transmission of *Ovine Gamma Herpesvirus 2*. *Journal Clinical Microbiology*. 2002; 40:4700-4701.
6. Imai K, Nishimori T, Murata H, Saito T, Yaegashi G. Experimental transmission of sheep associated malignant catarrhal fever from sheep to Japanese deer (*Cervus Nippon*) and cattle. *Veterinary Microbiology*. 2001; 79:83-90.
7. Kirbas A, Oruc E, Ozkanlar Y, Sozdutmaz I, Aktas MS, Saglam YS. Sheep associated malignant catarrhal fever: first report in a calf in Northeastern Turkey. *Isreal Journal of Veterinary Medicine*. 2013; 68:195-200.
8. Li H, Karney G, O'Toole D, Crawford T. Long distance spread of Malignant catarrhal fever virus from feedlot lambs to ranch bison. *Canadian Veterinary Journal*, 2008, 49:183-185.
9. Li H, Snowden G, Toole D, Crawford TB. Transmission of *Ovine Herpesvirus 2* in Lambs. *Journal Clinical Microbiology*. 1998; 36:223-226.
10. Li H, Westover WC, Crawford TB. Sheep associated malignant catarrhal fever in a petting zoo. *Journal of Zoo and Wildlife Medicine*. 1999; 30:408-412.
11. Luvizotto MCR, Ferrari HF, Cardoso TC. Malignant catarrhal fever like lesions associated with *ovine herpesvirus-2* infection in young calves (*Bos indicus*).

- Journal of Venomous Animals and Toxins including Tropical Diseases, 2010; 16:1-7.
12. O'Toole D, Li H, Robert S, Rovnak J, Demartini J, Cavender J *et al.* Chronic generalized obliterative Arteriopathy in cattle: A sequel to sheep associated malignant catarrhal fever. *Journal of Veterinary Diagnostic Investigation.* 1995; 7:108-121.
  13. Palmer MV, Thacker TC, Madison RJ, Koster LG, Swenson SL, Li H. Active and latent ovine Herpesvirus-2 infection in a Herd of captive white tailed Deer (*Odocoileus virginianus*). *Journal of Comparative Pathology.* 2013; 149:162-166.
  14. Premkrishnan GN, Sood R, Hemadri D, Chanu KV, Khandia R, Bhat S *et al.* Cross-sectional study indicates nearly a quarter of sheep population in Karnataka State of India is infected with Ovine herpesvirus-2. *Virus Diseases.* 2015; 26:180-188.
  15. Radostits OM, Gay CC, Hinchcliff K, Constable PD. *Veterinary medicine- A textbook of the diseases of cattle, horses, sheep, pigs, and goats*, 10<sup>th</sup> Edn., Saunders an imprint of Elsevier., Philadelphia, 2010, 1245.
  16. Russell GC, Stewart JP, Haige DM. Malignant catarrhal fever:a review. *Veterinary Journal.* 2009; 179:324-35.
  17. Sentsui H, Nishimori T, Nagai I, Nishioka N. Detection of sheep associated malignant catarrhal fever virus antibodies by complement fixation tests. *Journal of Veterinary Medicine Science.* 1996; 58:1-5.
  18. Sood R, Hamadri D, Bhatia S. Sheep associated malignant catarrhal fever: An emerging disease of bovids in India. *Indian Journal of Virology.* 2013; 24:321-331.
  19. Sood R, Kumar M, Bhatia S, Pateriya AK, Khandia R, Siddiqui A *et al.* *Ovine herpesvirus 2* infection in captive bison in India. *Veterinary Record.* 2012; 170:654.
  20. Vikoren T, Li H, Lillehaug A, Jonassen CM, Bockerman I, Handeland K. Malignant catarrhal fever in free ranging cervids associated with OvHV-2 and CpHV-2 DNA. *Journal of Wildlife Diseases.* 2006; 42:797-807.
  21. Vinod K, Sreedevi B, Karthik A, Vijayalakshmi S, Geethareddy A, Sreenivasulu D. Detection of OvHV-2 from an outbreak of Sheep associated malignant catarrhal fever from cross bred cattle of Southern India. *Veterinary Research Communication.* 2014; 38:323-328.
  22. Vurren M. Malignant catarrhal Fever. *Infectious Diseases of Livestock.* 2004; 2:1-19.
  23. Wani SA, Samanta I, Pandit F, Buchoo BA, Peer F, Bhat MA. Molecular epidemiology of *Ovine herpesvirus-2* infection in Kashmir, India. *Veterinary Record,* 2006; 159:587-590.
  24. Yesilbag K, Alpay G, Karakuzulu H. A serologic survey of viral infections in captive ungulates in Turkish zoos. *Journal of Zoo and Wildlife Medicine.* 2011; 42:44-48.