



E-ISSN: 2278-4136
P-ISSN: 2349-8234
JPP 2019; 8(3): 2769-2771
Received: 13-03-2019
Accepted: 15-04-2019

Anil Kumar
Assistant Professor, Department
of VCC, BVC, BASU, Patna,
Bihar, India

Ranveer Kumar Sinha
Assistant Professor, Department
of Veterinary Medicine, BVC,
BASU, Patna, Bihar, India

Archana
Assistant Professor, Department
of Veterinary Pharmacology and
Toxicology, BVC, BASU, Patna

GD Singh
Assistant Professor, Department
of VCC, BVC, BASU, Patna,
Bihar, India

Ajeet Kumar
Assistant Professor, Department
of Veterinary Biochemistry,
BVC, BASU, Patna, Bihar,
India

Correspondence
Anil Kumar
Assistant Professor, Department
of VCC, BVC, BASU, Patna,
Bihar, India

Clinical management of jaundice in calves associated with bovine anaplasmosis

Anil Kumar, Ranveer Kumar Sinha, Archana, GD Singh and Ajeet Kumar

Abstract

Bovine anaplasmosis is caused by *Anaplasma marginale*. The present report demonstrates the successful therapeutic management of bovine anaplasmosis in calves. Clinical examination of affected animals revealed anorexia, presence of ticks on the body, lacrimation, yellow discoloration of the mucus membrane of the eyes and rise in body temperature (103 -104.6⁰F). The blood smears examination revealed presence of *Anaplasma* organisms. The haematological and biochemical parameters revealed low level of Haemoglobin (Hb), Packed Cell Volume (PCV), Total erythrocyte count (TEC) and increased values of Serum glutamic-pyruvic transaminase (SGPT) and serum bilirubin respectively. Affected animals were successfully treated with oxytetracycline, haematinics and antipyretics.

Keywords: Anaplasma, calves, hemato-biochemical parameters, oxytetracycline

Introduction

Bovine anaplasmosis is a rickettsial haemoparasite, caused by *Anaplasma marginale* (El-Ashker *et al.*, 2015) [9] and transmitted by ticks, or mechanically by biting flies or blood-contaminated fomites (Jaswal *et al.*, 2013) [11]. Cattle of all age groups are prone to infected with *Anaplasma marginale*, but the clinical disease increases in severity with age and the infective dose of the organism (Abba *et al.*, 2016) [1]. The disease is most severe in adult cattle and causing high mortality, however, young calves of one-year-old usually manifest mild clinical signs with little or no mortality (Radostits *et al.*, 2000) [14]. The clinical manifestation of the disease varies; include fever, anaemia, weakness, constipation, jaundice, loss of appetite, dehydration, depression, laboured breathing, abortion in pregnant animals and often death (Richey and Palmer, 1990) [15]. *A. marginale* is highly pathogenic and leading to progressive anaemia and jaundice by invading and multiplying within red blood cells of the host without haemoglobinaemia and haemoglobinuria (Rymaszewska and Grenda, 2008) [16]. For effective control of anaplasmosis, early diagnosis and treatment is essential. Therefore, the present study deals with clinical management of Jaundice in calves associated with bovine anaplasmosis.

Materials and Methods

Three female calves of ILFC, BASU, Patna, aged between 9 months to 1.5 years old were presented with the complaint of anorexia, weakness, dullness and losing weight. The clinical examination revealed presence of ticks on the body, lacrimation, yellow discoloration or jaundiced appearance of the mucus membrane of the eyes and rise in body temperature (103 - 104.6⁰F) (Fig. 1). Blood samples were collected from jugular vein and analyzed before and one week after treatment for evaluation of hemato-biochemical parameters (Table 1) and Giemsa stain as per standard protocols.

Results and discussion

In the present study, Giemsa stained blood smear under microscopic examination revealed presence of *A. marginale* at the margins of erythrocytes (Fig 2) and clinical examination both revealed jaundice in all affected calves (Fig 1). The treatment was started with oxytetracycline (10 mg/kg body weight) intravenous infusion in 500ml of normal saline solution 12 hourly daily for 5 days, injection meloxicam with paracetamol @ 1ml/10 Kg body weight intramuscularly to combat fever and supportive therapy included liver extract (Belamyl injection) 5ml intramuscularly and haematinics (Ferritas bolus) 1 BID daily for 5 days. One week after treatment a remarkable improvement in clinical signs were observed but complete recovery from infection (parasite) and improvement in hemato-biochemical parameters was observed around 3 weeks post treatment. During treatment farm manager was advised to anti-tick spray to the diseased calves and the surrounding environment to control ticks.

Bovine anaplasmosis is a disease of cattle and can affect any age group. Clinically, the diagnosis of bovine anaplasmosis is made by blood smear examination and Giemsa-stained blood smears are used to perform the diagnosis in infected animals during the acute phase of the disease (Da Silva *et al.*, 2014)^[7]. Clinically, it is more commonly occur in cattle older than 1 year of age (Kocan *et al.*, 2003)^[12]. The clinical signs in the present study, was in close agreement with Kumar *et al.*, 2015^[13] and Bal *et al.*, 2017^[4]. The mean values of haematological parameters (Table 1) before treatment revealed low level of haemoglobin (Hb), packed cell volume (PCV) and total red blood cell count (TEC). These findings are similar to those reported by Kumar *et al.*, 2015^[13] and Doyle *et al.*, 2016^[8] which might be due to decreased erythrocyte life span and extravascular erythrophagocytosis in bovine anaplasmosis. The biochemical parameters before treatment revealed increased level of total protein (TP) and albumin. The finding of the present studies is in agreement with the results of Coskun *et al.*, 2012^[6] and Ashuma *et al.*, 2013^[2], which might have resulted from dehydration. Similarly, increased values of SGPT and total serum bilirubin concentration were in agreement with Jassem and Akaar (2015)^[10], who stated that increased enzyme AST and ALT activity may be attributed to severe anemia that leads to hypoxia and massive hemolysis in conjunction with hypoxia may lead to hepatic cell degeneration and glomerular dysfunction. The increase in serum bilirubin concentration might be due to hemolysis of parasitized erythrocytes by the reticulo-endothelial system (Sandhu *et al.*, 2011). For therapeutic management, tetracyclines have been found to be very effective especially if given early in the multiplication phase of the incubation period (Brinkman and Kersting, 1990)^[5]. Atif *et al.*, (2012)^[3] also concluded that oxytetracycline is more effective and safe in chemical sterilization of persistent *Anaplasma marginale* infection in cattle. In the present study, all calves responded to treatment, which was in accordance with Bal *et al.*, (2017)^[4] who successfully treated affected animals with oxytetracycline, haematinics and antipyretics.

Table 1: Mean values of hematobiochemical parameters in affected calves.

Parameters	Before treatment	3 weeks After treatment
Hb (g/dl)	8.4	10.6
PCV (%)	26	32
TEC (x10 ⁶ /cumm)	4.32	5.40
Total Protein (g/dl)	6.58	6.41
Albumin (g/dl)	3.56	3.32
Total serum bilirubin (mg/dl)	4.09	0.76
SGPT(U/L)	59.2	27

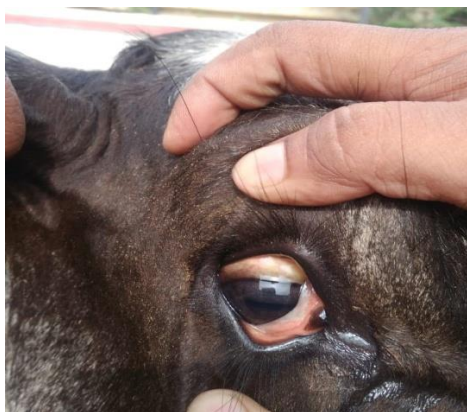

Fig 1: Showing icteric eyes and lacrimation

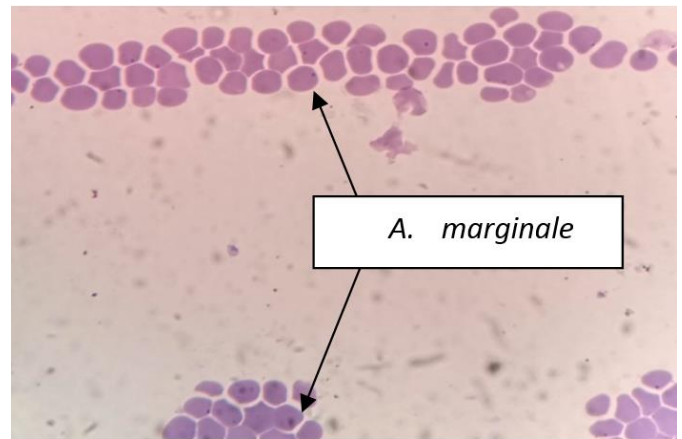


Fig 2: Showing *A. marginale* at the margins of RBCs

Conclusion

Bovine anaplasmosis is a rickettsial haemoparasite and its diagnosis is mainly based on examination of Giemsa-stained peripheral blood smears. Haemato-biochemical parameters had low level of Hemoglobin, PCV and TEC and high level of SGPT and serum bilirubin. Oxytetracycline along with supportive therapy proved to be a safe and effective treatment in cattle.

References

1. Abba Y, Jesse FFA, Sadiq MA, Ibrahim HH, Chung ELT, Bitrus *et al.* Clinical management and gross pathological findings of a severe anaplasmosis in a dairy cow. *Journal of Advanced Veterinary and Animal Research.* 2016; 3(2):195-199.
2. Ashuma, Sharma A, Singla LD, Kaur P, Bal MS, Batth *et al.* Prevalence and haemato-biochemical profile of *Anaplasma marginale* infection in dairy animals of Punjab (India). *Asian Pacific Journal of Tropical Medicine,* 2013, 139-144.
3. Atif FA, Khan MS, Khan MA, Ashraf M, Avais M. Chemotherapeutic efficacy of Oxytetracycline, Enrofloxacin and Imidocarb for the elimination of persistent *Anaplasma marginale* infection in naturally infected Sahiwal Cattle. *Pakistan J Zool.* 2012; 44(2):449-456.
4. Bal MS, Mahajan V, Folia G, Singh CK, Kaur P, Sharma S. Outbreaks of Anaplasmosis in Dairy Cattle in Punjab, India. *Journal of Animal Research.* 2017; 7(5):885-889.
5. Brinkman MH, Kersting W. Bovine Anaplasmosis: An Overview. *Iowa State University Veterinarian.* 1990; 52(1):34-38.
6. Coskun A, Ekici OD, Ayadogdu Hasan GU, Sen I. Acute Phase Proteins, Clinical, Hematological and Biochemical Parameters in Dairy Cows Naturally Infected with *Anaplasma Marginale*. *Kafkas Univ Vet Fak Derg.* 2012; 18(3):497-502.
7. Da Silva JB, de Santana CGN, Fonseca AH. Longitudinal study of risk factors for anaplasmosis and transplacental transmission in herd cattle. *Semina: Ciencias Agrarias, Londrina.* 2014; 35(4):2491-2500. DOI 10.1007/s12639-013-0384-4.
8. Doyle RL, França RT, Oliveir CB, Rezerb JFP, Klafke GM, Martins *et al.* Cattle experimentally infected by *Anaplasma marginale*: Influence of splenectomy on disease pathogenesis, oxidative profile, and antioxidant status. *Microbial Pathogenesis.* 2016; 95:193-199.

9. El-Ashker M, Salama M, El-Sebae M, Risha E, Abdelhamid F, El-Diasty *et al.* Significance of clinical variables and selected biochemical markers in predicting the outcome of bovine anaplasmosis. *Veterinari Medicina*. 2015; 60(6):301-308.
10. Jassem Abbas G, Agaar Olaa A. Molecular and biochemical study of *Anaplasma marginale* in cattle in Wassit Province of Iraq. *Journal of Bacteriology Research*. 2015; 74(4):36-41.
11. Jaswal H, Bal MS, Singla LD, Gupta K, Brar APS. Pathological observations on clinical *Anaplasma marginale* infection in cattle. *J Parasit Dis*. 2013. DOI 10.1007/s12639-013-0384-4.
12. Kocan KM, De la Fuente J, Guglielmone AA, Melendez RD. Antigens and Alternatives for Control of *Anaplasma marginale* infection in Cattle. *Clin. Microbiol. Rev.* 2003; 16(4):698-712.
13. Kumar T, Sindhu N, Charaya G, Kumar A, Kumar P, Chandratere *et al.* Emerging status of anaplasmosis in cattle in Hisar. *Veterinary World*. 2015; 8:768-771.
14. Radostits OM, Gay CC, Blood DC, Hinchcliff KW. *Veterinary Medicine*, 9th Edn., WB Saunders. London, 2000.
15. Richey EJ, Palmer GH. Bovine anaplasmosis. *Compend Contin Educ Pract Vet*. 1990; 12:1661-1668.
16. Rymaszewska A, Grenda S. Bacteria of the genus *Anaplasma*, characteristics of *Anaplasma* and their vectors: a review. *Vet Med*. 2008; 53(11):573-584.
17. Sandhu GS, Grewal AS, Singh A, Kondal JK, Singh J, Brar RS. Haematological and biochemical studies on experimental *Theileria annulata* infection in crossbred calves. *Vet Res Commun*. 1998; 22:347-354.